

An Interesting Case of Endometrial Stromal Nodule

Hariharan Valson*, Bhavuray Teli**

*Associate Professor, Department of Obstetrics and Gynecology **Assistant Professor, Department of Surgery, DMWIMS, Meppadi-673577. Wayanad, Kerala, India.

Abstract

Endometrial stromal tumours (EST) are a type of uterine mesenchymal tumour which account for less than 10% of all uterine sarcoma and approximately 1 % of all uterine malignancies.

Endometrial stromal nodule (ESN) is the least common type of EST and it forms less than 0.25% of all EST. It should be carefully differentiated from other stromal sarcomas, which can change the final prognosis. We are presenting a patient with an interesting case of ESN who underwent a total abdominal hysterectomy.

Keywords: Endometrial Stromal Tumours; Endometrial Stromal Sarcomas; Endometrial Stromal Nodule; Sarcomas.

Introduction

The endometrial stromal tumours are rare variety mesenchymal tumors with cytological features reminiscent of endometrial stromal cells [1].

The classification of endometrial stromal tumor is difficult and complicated [2, 3]. The recent World Health Organization classification of uterine stromal tumors is ESN, undifferentiated endometrial sarcoma (UES), endometrial stromal sarcoma (ESS).

The ESN is a benign tumor with well-differentiated endometrial stromal cells forming a well-circumscribed nodule with largely smooth, non-infiltrative margins. ESN occurs at any age during reproductive or later years. Most are incidental

findings in a hysterectomy specimen. Few cases present with abnormal uterine bleeding.

Pelvic imaging cannot reliably differentiate these tumors from leiomyomas or sarcomas.

Majority are immuno-reactive for progesterone and estrogen receptors. Typically, they are positive for CD-10 and negative for Desmin and H Cadesmin.

Case study

A 46 years old perimenopausal lady presented with excessive bleeding during menses for one year with secondary dysmenorrhea. She had a flow of 7 to 8 days duration with dysmenorrhea for the first 2 days. On general examination mild pallor was there. In systemic examination, there was a firm mass in the midline, arising out of pelvis, nontender, and approximately 14 weeks size. The cervix was normal and uterus was enlarged, firm and approximately 14 weeks size. Ultrasound pelvis revealed enlarged and bulky uterus with endometrial thickness of 12mm with intra-mural fibroid of 8 cm x10 cm. Pre-operative diagnosis of fibroid with abnormal uterine bleeding was made. Total abdominal hysterectomy with bilateral salpingo oophorectomy was done.

Histopathological examination (HPE)

Macroscopy

A light yellowish colored mass of approximately 10 x 8 cm, infiltrating into the endometrial cavity and surrounding myometrium.

Microscopy

Section study showed a circumscribed tumor composed of cells, arranged in closely packed clusters, sheets and concentrically around blood

Corresponding Author: Bhavuray Teli, Assistant Professor, Department of surgery, DMWIMS, Meppadi-673577, Wayanad, Kerala, India.
Email: teli.bhavu@gmail.com

vessels. Tumor cells have scanty cytoplasm, round to polygonal vesicular nuclei, lacy network of hyalinated stromal matrix and scanty lymphocytic infiltrate.

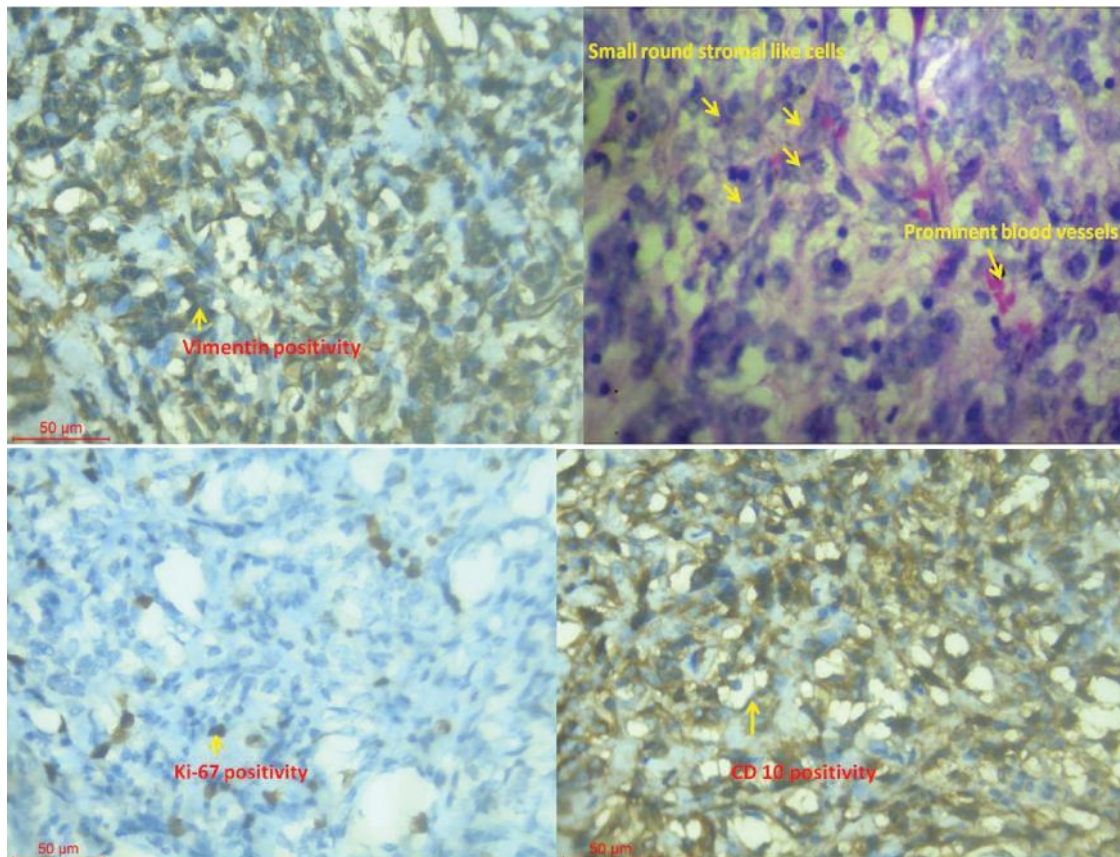
Immunohistochemistry (IHC)

The IHC revealed the oval cells positive for

Vimentin and CD10. Ki 67 proliferation index is 6-8%. Hence a final diagnosis of endometrial stromal nodule was made.

The patient has been followed up periodically for a period of one and half year and is in good health.

Fig. 1: Photograph of immunohistochemistry



Discussion

ESTs are the least common neoplasms of the uterine corpus, with an annual incidence of about two per million women [1–4]. ESN is a rare subtype which accounts for less than five percent of uterine tumors [5–7].

EST is classified by tumor invasiveness, with respect to margins and the degree of stromal differentiation. Therefore immunohistochemistry (IHC) and the presence of molecular alterations are used to classify these tumors more precisely.

Although large series of ESTs often include ESN, they are usually few in number [8]. There is only one large series of cases reported by Tavassoli and Norris in 1981, about 60 cases of ESN [9] and one probable group of 11 cases in the older literature [10]. Dionigi

published a series there were only four endometrial stromal nodules [11]. Amanjit published 1261 endometrial neoplasms from January 2001 to December 2004, in which 5 cases of EST and one case was diagnosed as ESN [12]. ESN has been defined as a well-circumscribed EST and may have focal irregularities or finger-like projections into the adjacent myometrium are acceptable if none of them exceed 2 to 3 mm [8,9]. This tumour commonly involve the myometrium or endometrium or both.

ESNs occur primarily in peri- and postmenopausal women. Tavassoli and Norris [8,9] reviewed 60 women with ESNs; the median age was 47 years. The patients may present with vaginal bleeding, anemia, pelvic or abdominal pain or discomfort, or may be asymptomatic [5,6,8,13]. Our patient had secondary dysmenorrhea with menorrhagia. The most common preoperative

diagnoses were leiomyoma and adnexal masses [1,13].

As the majority of patients are beyond childbearing years, a hysterectomy is usually required; it permits the thorough evaluation of the tumor margin too, which is necessary to distinguish a benign stromal nodule from a stromal sarcoma [3,14]. However, in contrast to stromal sarcomas, patients with stromal nodules have remained free of disease and no recurrences were noted following hysterectomy [9,13].

In a curettage specimen, distinction between ESN and low-grade ESS is difficult, unless the tumor is very small and the margins can be fully evaluated. In women of reproductive age who desire to preserve fertility, diagnostic imaging and hysteroscopy may be used to follow up tumor growth. In some cases, hormonal therapy with local excision may be successful. In the series reported by Tavassoli and Norris, six patients underwent simple excision of the uterine nodules. One patient had a hysterectomy 4 years later for endometrial hyperplasia, and the pathologic evaluation revealed no evidence of stromal tumor. The other five patients were followed upto 10 years with no evidence of recurrence [9]. Schilder [13] published a successful hormonal therapy (leuprolide acetate) in decreasing the size of a low-grade endometrial stromal sarcoma, local excision of the tumor with preservation of reproductive function. Although the receptor status of stromal nodules has not been studied, their similarity on a cellular level to low-grade stromal sarcomas suggests that a trial of hormonal therapy in this case, when conservative management was desired, might be successful.

Our patient aged 46 years was avid neither for pregnancy nor for a conservative treatment, hence underwent a total abdominal hysterectomy with bilateral salpinx oophorectomy.

Macroscopically, the tumor is characteristically a solitary, well-delineated, round fleshy nodule with a yellow to tan sectioned surface. The median tumour diameter is 4 cm (range 0.8 to 15 cm). It was 8 x 7 x 3 cm in our case. About two thirds are purely intramural without any apparent connections to the endometrium. In our case it had infiltrated the endometrial cavity (hence the reason for menorrhagia) and remaining part was in the myometrium. Occasionally tumors are cystic, but foci of necrosis and hemorrhage are rare.

Differential diagnosis of an ESN depends on microscopic findings.

The histological appearance found endometrial stromal nodules with areas of epithelial-like structures that resemble ovarian sex cord tumors. The

stromal nodules have expansile, noninfiltrative margins that compress the surrounding endometrium and myometrium. Minor irregularities of the margin are common, but invasion of the surrounding myometrium indicates that the tumor is a stromal sarcoma, not a stromal nodule [11,15].

In our case, the tumor expressed the CD10, vimentin and the Ki-67 proliferation index was 6 to 8%. Immunostaining for AML (alpha smooth muscle), desmine, calretinin, cytokeratin AE1/AE3, and inhibin were negative.

ESN with focal sex cord-like differentiation tend to relapse and metastase. In Clement and Scully initial report, three of five patients with follow up had recurrences and two died [16].

Conclusion

There is no reliable preoperative diagnostic procedure to identify this tumour. Clinical presentation is nonspecific. Hysterectomy is the treatment of choice. The diagnosis is done on microscopic and IHC examination. The margins of tumour must be determinate to differentiate it from invasive stromal tumors. Considered as benign tumor, the prognosis is excellent when the diagnosis is sure.

Reference

1. S. Elagoz, F. Kuvanc, H. Aker, et al., "Endometrial stromal tumors—a report of 5 cases," *Aegean Pathology Journal*. 2005; 2:140–145.
2. N. C. Ramirez and W. D. Lawrence, "Endometrial stromal lesions," in *Weitner Cote Suster Weiss. Modern Surgical Pathology*. 1st ed. Saunders, Philadelphia, Pa, USA, 2003; 1327–1377
3. C. Zaloudek and M. R. Hendrickson, "Mesenchymal tumors of the uterus," in *Blaustein's Pathology of the Female Genital Tract*, R. J. Kurman. 5th ed., Springer, New York, NY, USA, 2001. P. 561–615
4. F. A. Tavassoli and P. Devilee, *World Health Organization Classification of Tumors. Pathology and Genetics of the Breast and Female Genital Organs*, IARC Press, Lyon, France, 2003.
5. K. Ryuko, K. Takahashi, and K. Miyazaki, "A case of endometrial stromal nodule," *Shimane Journal of Medical Science*. 1996; 14:27–28.
6. S. G. Silverberg and R. J. Kurman, *Tumors of the Uterine Corpus and Gestational Trophoblastic*

- Disease, Atlas of Tumor Pathology 3rd Series, AFIP, Washington, DC, USA, 1992.
7. W. J. Hoskins, C. A. Perez, and R. C. Young, Principles and Practice of Gynecologic Oncology, JB Lippincott, Philadelphia, Pa, USA, 1992.
 8. K. R. Kim, S. Y. Jun, I. A. Park, J. Y. Ro, and J. H. Nam, "Endometrial stromal tumor with limited infiltration and probable extrauterine metastasis: report of a case," Annals of Diagnostic Pathology.2005; 9: 57-60.
 9. F. A. Tavassoli and H. J. Norris, "Mesenchymal tumors of the uterus. VII. A clinicopathological study of 60 endometrial stromal nodules," Histopathology, vol. 5, no. 1. 1981. p. 1-10,
 10. L. Michaelis and F. A. Langley, "Mesenchymal tumours of the uterus resembling the haemangiopericytoma," The Journal of Obstetrics and Gynaecology of the British Empire.1957; 64: 561-565.
 11. A. Dionigi, E. Oliva, P. B. Clement, and R. H. Young, "Endometrial stromal nodules and endometrial stromal tumors with limited infiltration: a clinicopathologic study of 50 cases," American Journal of Surgical Pathology.2002; 26: 567-581.
 12. A. Bal, H. Mohan, R. Aulakh, and A. Huria, "Endometrial stromal lesions: a morphological and immunohistochemical study of short series," Archives of Gynecology and Obstetrics.2008; 277:21-4.
 13. J. M. Schilder, W. W. Hurd, L. M. Roth, and G. P. Sutton, "Hormonal treatment of an endometrial stromal nodule followed by local excision," Obstetrics & Gynecology.1999; 93: 805-07.
 14. A. Yilmaz, D. S. Rush, and R. A. Soslow, "Endometrial stromal sarcomas with unusual histologic features: a report of 24 primary and metastatic tumors emphasizing fibroblastic and smooth muscle differentiation," American Journal of Surgical Pathology.2002; 26: 1142-1150.
 15. K. L. Chang, G. S. Crabtree, S. K. Lim-Tan, R. L. Kempson, and M. R. Hendrickson, "Primary uterine endometrial stromal neoplasms. A clinicopathologic study of 117 cases," American Journal of Surgical Pathology.1990; 14: 415-438.
 16. V. Geetha, S. Rupashree, and S. Bhat, "Endometrial stromal nodule with smooth muscle differentiation," Indian Journal of Pathology & Microbiology.2008; 51: 76-77.

Red Flower Publication Pvt. Ltd,

CAPTURE YOUR MARKET

For advertising in this journal

Please contact:

International print and online display advertising sales

E-mail: redflowerppl@vsnl.net / tel: +91 11 22754205, 45796900

Recruitment and Classified Advertising

E-mail: redflowerppl@vsnl.net / tel: +91 11 22754205, 45796900